

Large L5-S1 Disc Protrusion Treated Successfully With Cox® Technic

A case study presented to the
**Part III — Hospital-Based Training Course for
Cox® Technic in the Interdisciplinary Progression of Care for Back & Radicular Pain**
December 5-6, 2009

Dean M. Greenwood, DC
Certified in Cox® Technic
Vancouver Spine Care Centre
Vancouver, BC, Canada

History/Chief Complaint

A 41 year old Asian/Canadian female is seen with severe low back pain extending down the left leg to the left lateral calf region. Onset of pain was sudden and insidious of one day's duration. She is employed as a bookkeeper and is not involved in heavy lifting or physical labor. The history also revealed chronic low back stiffness with progressive tension up the spine over several months. The patient had been attending another chiropractor for occasional high velocity treatment to the lumbar spine with temporary relief and was seen by the author 10 years prior to this acute episode. Pain was described as severe, sharp and constant pulling into the left leg and a VAS score of 10/10. Sitting was painful, as was all movement. Assistance was required for the patient to ambulate through the office. A history of mild to moderate high blood pressure was also revealed.

Examination

Forward and slight left antalgia with pronounced left lumbar paraspinal muscle spasm was evident. Heel and toe walk were normal but were difficult to perform. Standing range of motion testing was limited in all directions with extreme guarding. Palpation over the left L5 segmental level and the left calf manifested marked localized pain with referral to the left lower leg. Bechterews test was positive and Kemps sign while seated increased the low back pain, with increased pain to the left leg. Straight Leg Raise on the left caused a lifting of the left ilium due to severe guarding, a positive Cox's sign. Straight Leg Raise test (SLR) on the right elicited pain in the left lower lumbar region at 60 degrees with some referral to the left calf. Left and right Achilles deep tendon reflexes were absent and patellar deep tendon reflexes were +1 bilaterally. No weakness was noted on plantar or dorsi flexion of the great toes bilaterally.

Imaging

Standing plain film radiographs of the lumbar spine were taken at my office and demonstrated mild to moderate disc thinning between L4-5 and L5-S1 with anterior osteophytes at L4-5. Posterior joint hypertrophy was also noted at L4-5 and L5-S1. The plain films suggested a long standing degenerative condition of the lower lumbar spine, but were not conclusive for this acute presentation. Additional imaging was recommended to assist in the diagnosis and referral to the family physician was made. Patients in British Columbia may access subsidized out-patient services, such as CT scans when referred by a family physician. The patient's physician was on holiday and the necessary referral was not obtained. Dr. Michael Carter, an attending emergency physician at the University of British Columbia Urgent Care Clinic, and a personal acquaintance of the author was contacted. The patient was seen by Dr. Carter on an urgent basis and a CT scan was expedited. Imaging is shown in Figures 1 and 2.

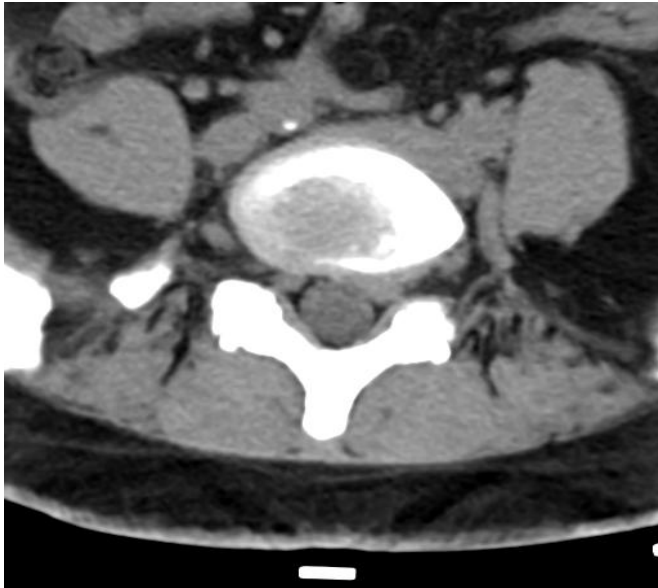


Figure 1 Axial CT image of L5-S1 disc exhibits a large intraforaminal disc protrusion traversing the left S1 nerve root (reading right) as well as posterior joint arthropathy and thickening of the ligamentum flavum. Of coincidental note is a small calcific lesion anterior to the spine indicative of mild atherosclerotic plaquing in the descending right common iliac artery. Arterial plaquing was also visualized on several other images in this series.

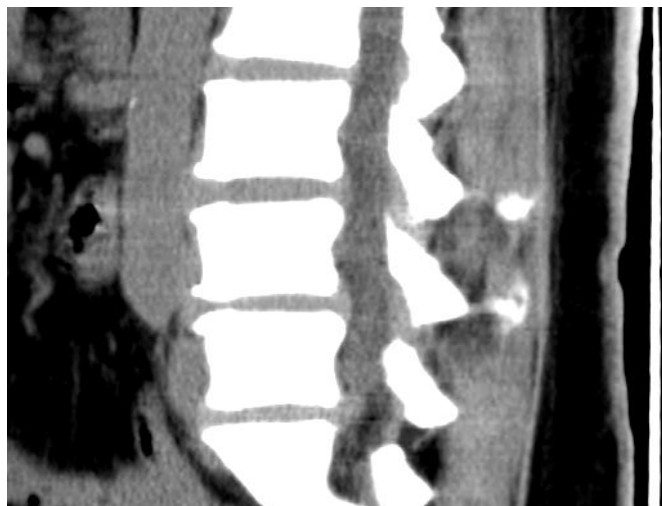

Figure 2 Sagittal CT image showing large L5-S1 disc protrusion with degenerative disc changes at L4-5 and L5-S1 and mild bulging of the L4-5 disc.

Diagnosis

1. Large, left intraforaminal disc protrusion, traversing the left S1 nerve root
2. Degenerative spondylosis of the lower lumbar spine with mild disc bulging at L4-5
3. Coincidental findings of atherosclerotic plaquing of the abdominal aorta and left and right common iliac arteries

Treatment

The patient was instructed to lie prone on the Cox®7 instrument with the table in slight caudal flexion to reduce muscle guarding. Protocol 1 of the Cox® Technic was initiated to patient tolerance. Relief was immediate with flexion distraction, and cold laser was applied to the L5 disc area, the hip and to the trigger points in the lateral calf. Returning to the upright position was done with great difficulty and a lumbar support brace was prescribed. A chondroitin and chymotrypsin anti-inflammation formula was prescribed to assist in recovery. An ice pack was provided for home use 30 minutes at a time 4 to 5 times a day and moist heat applications were recommended alternatively with ice to reduce muscle spasm. Treatments were prescribed at 3 times a week as the patient had to drive a distance to our clinic. By the fourth visit pain was reduced somewhat, and treatment continued utilizing Cox® 1 protocol to patient tolerance. After 3 more treatment 50% improvement was achieved and the treatment then progressed to Protocol 2 to patient tolerance. Knee to chest exercises were prescribed and sitting was discouraged. A flare up occurred following a brief interruption of care due to Christmas holidays, but then settled down again upon returning to care. Over the next two months, Protocol 2 treatments were administered and the back pain abated nicely. Leg pain was reduced to VAS 7, but persisted.

4

MRI imaging was recommended through the patient's MD. Lyrica was prescribed for the leg pain but no other tests were recommended. The Lyrica was discontinued by the patient due to adverse side effects. Back pain and leg pain were relieved and at the 3 month interval pain was improved sufficiently to reduce treatments to once a week. By the end of month 4 of treatment, pain had abated to a VAS score of 2 and was only mildly annoying. Supportive care is ongoing at one to two weeks intervals. The patient reports significant improvement in quality of life and reduction of symptoms to a negligible level.

Discussion

As Dr. Cox writes in his text "Low Back Pain, Mechanism, Diagnosis and Treatment" regarding a positive Cox's sign: **1**

"Cox's sign occurs when, during SLR, the pelvis rises from the table rather than the hip flexing. I have noticed this occurrence in patients with prolapse into the intervertebral foramen-a grave condition."

This type of case requires advanced training in disc pathophysiology as is provided by Dr. Cox and his associates in the Cox® Technic Seminars. This particular case also highlights a cooperative interdisciplinary management approach keeping the patient's best interests in mind at all times. This patient has expressed sincere gratitude many times during the course of care and never lost sight of the ultimate goal, which was to relieve her pain and return her to normal function without drugs or surgery.

Conclusion

This case demonstrates the efficacy of Cox® Technic in the treatment of a very large intraforaminal disc protrusion with severe sciatic radiculopathy.

Acknowledgements

I would like to acknowledge the assistance of Michael Carter, MD and the staff of the Urgent Care Clinic at UBC Hospital in Vancouver, BC.

I would also like to acknowledge Julie Cox for her encouragement and technical assistance in the preparation of this report.

References

1. Cox, JM: Low Back Pain, Mechanism, Diagnosis, Treatment, 6th Edition
Philadelphia: Lippincott, Williams and Wilkins 1999: pgs 438-439

5

Respectfully submitted,

Dean M. Greenwood, DC
Certified Cox Technic Physician
September 13, 2009

www.vancouverpinecarecentre.com

drdeang@shaw.ca